

Variations Encountered in Umbilical Cord Insertion in Human Placentae from a Tertiary Care Hospital

Dr. Neelima. P¹, Dr. R. Ravi Sunder²

¹Professor, Department of Anatomy, ²Professor, Department of Physiology,

^{1,2}GITAM Institute of Medical Sciences and Research,

^{1,2}GITAM UNIVERSITY, Rushikonda, Visakhapatnam, Andhra Pradesh, India

ABSTRACT

Umbilical cord shows variations in its insertion at the placenta. This reflects the underlying modifications of fetal circulation in the intrauterine life. Knowledge regarding the prevalence of variations in the umbilical cord insertion is essential for obstetricians and paediatricians to predict the developmental abnormalities in fetal circulation. The present study was done to evaluate the various types of umbilical cord insertions encountered in the human placentae delivered in a tertiary care hospital. 80 placentae with umbilical cords were collected for 6 months from the hospital with the concerned permissions. They were washed thoroughly and fixed in 10% formalin for preservation. Each placenta was observed carefully for the umbilical cord insertion. The results were analysed and represented graphically. There were no considerable knots observed in the stumps of the cords. All the cords had normal three vessels on cross-section i.e., two umbilical arteries and one umbilical vein. When the patterns of insertions were examined, 71% showed normal central insertion, 29% were abnormal where 19% marginal, 7% furcate and 3% exhibited velamentous insertion. When compared with other studies, they correlated. The present study depicts the various abnormal types of umbilical cord insertions from the human placentae collected from a tertiary care hospital.

KEYWORDS: Umbilical cord, velamentous insertion, placentae

INTRODUCTION

Umbilical cord is a 45-60 cm tube connecting the foetus and the mother. It facilitates transport of oxygen and nutrients through the umbilical vessels contained in the whartons jelly. It develops by fifth week of intrauterine life. Attachment of the umbilical cord is usually eccentric and occasionally even marginal. Rarely, however, it inserts into the chorionic membranes outside the placenta (velamentous insertion)⁽¹⁾. The congenital anomalies can be identified in the early gestational period⁽²⁾. Pretorius et al⁽³⁾ described the marginal insertion of umbilical cord. Other types of abnormal insertions were explained by Inderbir singh⁽⁴⁾. Benirschke⁽⁵⁾ elaborated about the velamentous insertion. The various abnormal insertions reflect the underlying changes in the dynamics of the fetal circulation. Many studies have been done on the occurrence of abnormal umbilical cord insertions. The present study illustrates the variations of umbilical cord insertion from a tertiary care hospital from north coastal Andhra Pradesh.

MATERIALS & METHODS

80 placentae with umbilical cords have been collected from the OBG department of the hospital which included delivery by both caesarean section and normal. The placentae were collected over a period of six months and preserved in the department of anatomy for evaluation. Each placenta with the umbilical cord was washed and fixed in 10% formalin. The results were graphically represented and compared with other studies.

RESULTS

The umbilical cords were examined for the type of insertion at the placenta. All umbilical cords were found to have normal three vessel pattern i.e., two umbilical arteries and one umbilical vein on examining the cut section. There were no observable knots in the stumps of the cords. The following figures depict the types of insertions.

How to cite this paper: Dr. Neelima. P | Dr. R. Ravi Sunder "Variations Encountered in Umbilical Cord Insertion in Human Placentae from a Tertiary Care Hospital" Published in International Journal of Trend in Scientific Research and Development (ijtsrd), ISSN: 2456-6470, Volume-4 | Issue-5, August 2020, pp.1671-1674, URL: www.ijtsrd.com/papers/ijtsrd33245.pdf



IJTSRD33245

Copyright © 2020 by author(s) and International Journal of Trend in Scientific Research and Development Journal. This is an Open Access article distributed under the terms of the Creative Commons Attribution License (CC BY 4.0) (<http://creativecommons.org/licenses/by/4.0>)



Fig 1: umbilical cords examined



Fig 2: normal insertion of the umbilical cord

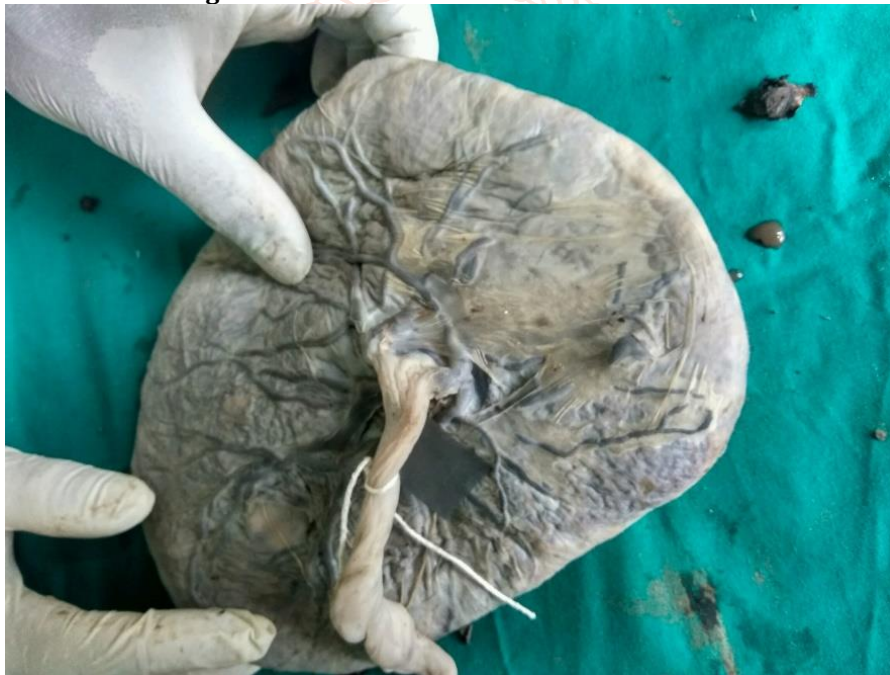

Fig 3: marginal insertion of umbilical cord

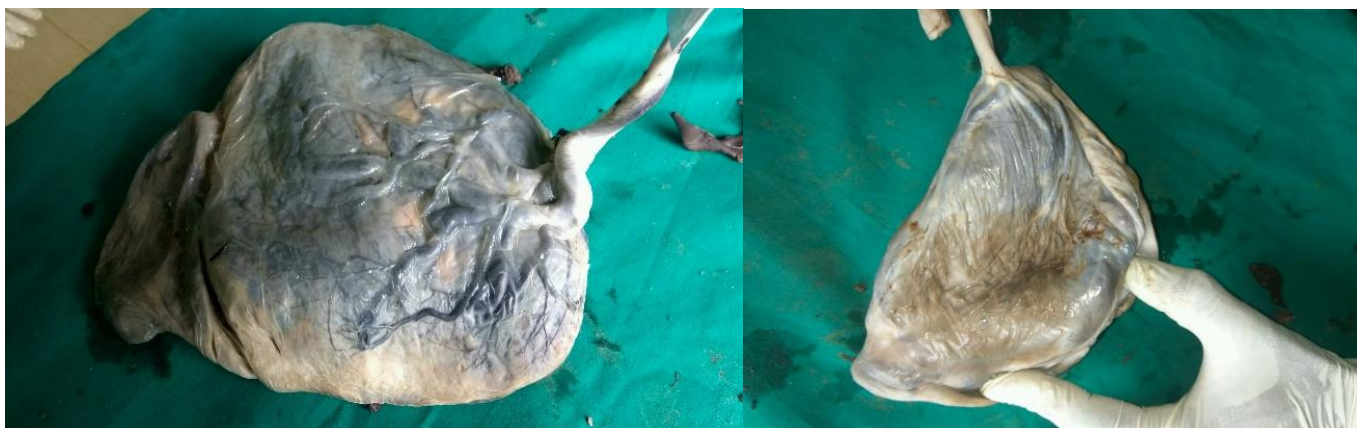

Fig 3: velamentous insertion

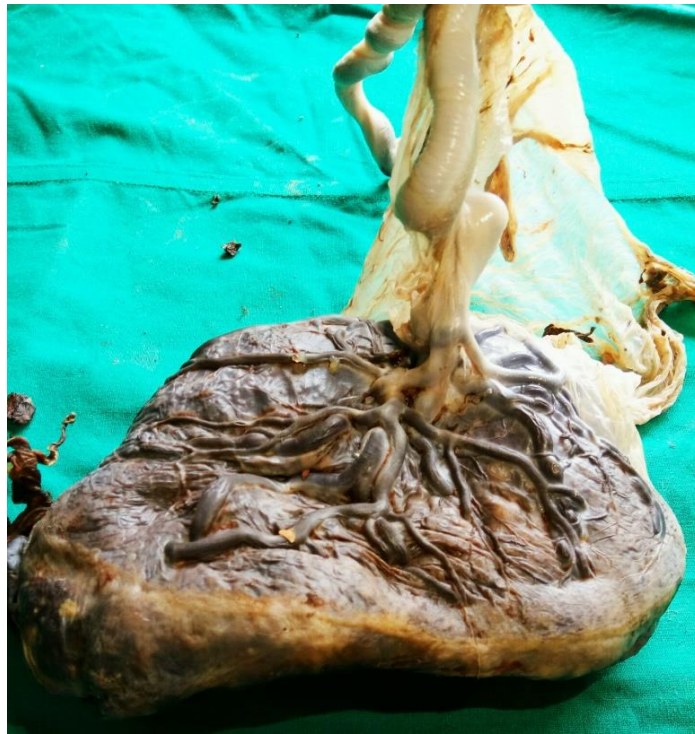
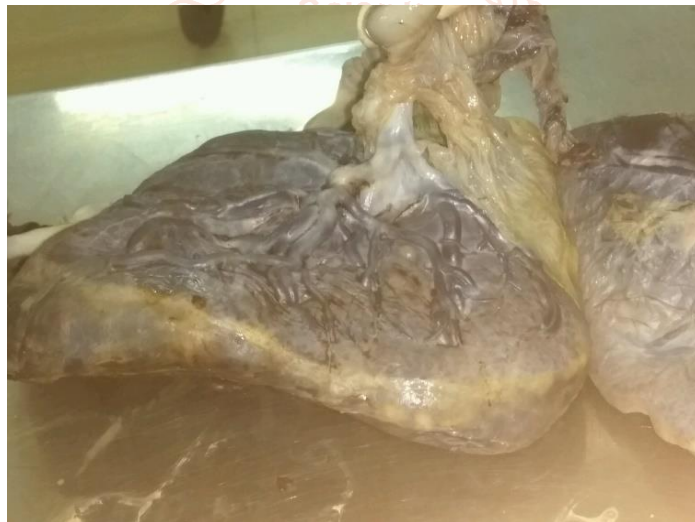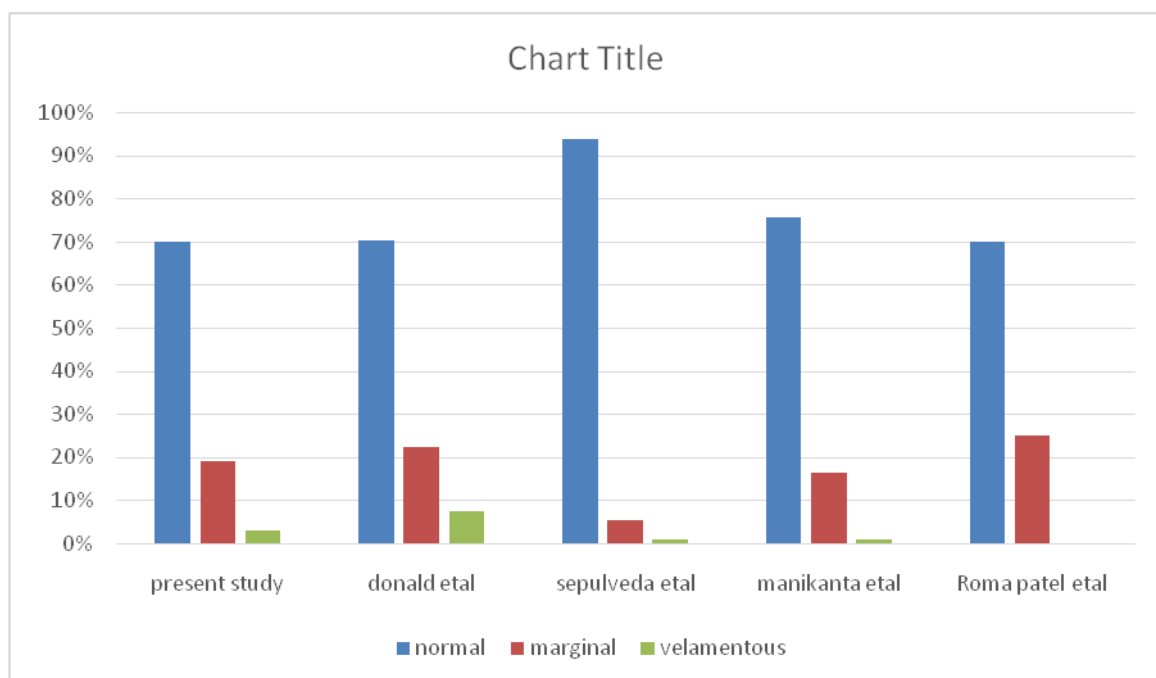


Fig 4: furcate insertion



Graph 1: comparison with other studies



DISCUSSION

Umbilical cord normally attaches at the centre of the fetal side of the placenta. However, variations of the insertion exist. They are of different types- marginal being the most common, furcate and velamentous insertions are observed. Studies have been done by various authors to analyze the variations ^(6,7). The present study has been done to observe the different patterns of insertions of the umbilical cord from a tertiary care hospital from north coastal Andhra Pradesh. The results were compared with the study made by Manikanta etal⁽⁸⁾, Sepulveda etal ⁽⁹⁾, Donald etal ⁽¹⁰⁾ and Roma patel etal⁽¹¹⁾. The observations correlated with these studies.

CONCLUSION

The variations in the umbilical cord insertions from a tertiary care hospital have been examined. The results were compared with other studies and correlated.

CONFLICT OF INTEREST: none

SOURCE OF FUNDING: nil

REFERENCES

- [1] Langmans-Medical-Embryology-12th-ed.-T.-Sadler-Lippincott-2012, pg 121.
- [2] Kinare A. Fetal environment. Indian J Radiol Imaging. 2008; 18(4): 326-344.
- [3] Pretorius DH, Chau C, Poeltler DM et.al. Placental cord insertion visualization with prenatal ultr a sonography. J Ultrasound Med 1996; 15:585-593.
- [4] Inderbir Singh, G. P. Pal. Human Embryology in The Placenta.8th Edn. Macmillan Publishers India Ltd, India 2009, pp59- 75.
- [5] Benirschke K, Kauffman P. Anatomy and pathology of the umbilical cord and major fetal vessels. In: Bernirshke K, Kauffman P, eds. Pathology of the human placenta. 4th ed. New York: Springer-Verlag; 2000:26-386.
- [6] Arora NK, Khan AZ et al. Variations in placental attachment of umbilical cord. Ann Int Med Dent Res 2016; 2:110-2.
- [7] Yousuf MS, Tarannum Y, Naval KP. Variations in the placental attachment of umbilical cord and its clinical significance. J Med Dent Sci 2015; 4(70):1-7.
- [8] Manikanta R, Geetha SP, Nim VK. Variations in placental attachment of umbilical cord. J Anat Soc India 2012; 61:1-4
- [9] W. Sepulveda, I. Rojas, J. A. Robert et al. Placental detection of velamentous insertion of the umbilical cord: a prospective colour Doppler ultrasound study. Ultrasound Obstet Gynecol2003; 21: 564- 569
- [10] Donald N. Di Salvo, carol B. Benson, Faye C. Laing. Sonographic evaluation of the placental cord insertion site. Americal journal of Radiology 1998; 170: 1295-1298.
- [11] Roma Patel, Sumit Babuta. Variation of Human Placental Attachment of Umbilical Cord. Int J Med Res Prof. 2019 Sept; 5(5):265-67. DOI:10.21276/ijmrp.2019.5.5.059.

